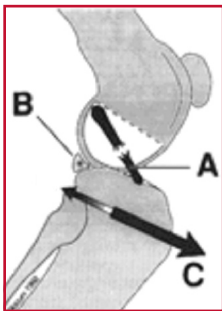


# Tibial Plateau Leveling Osteotomy (TPLO)

## Introduction

Cranial cruciate ligament (CCL) tear is the most common traumatic orthopedic injury seen in dogs of all ages and breeds. By the late 1990's Tibial Plateau Leveling Osteotomy (TPLO) has become a commonly performed technique to address the condition due to its significant success in large and active canine patients.

## Anatomy of the stifle (knee)



A- torn CCL B- Caudal medial meniscus  
C- Forward thrust

The cruciate ligaments are important stabilizing elements within the canine stifle joint. There are two cruciate ligaments in the knee, called the cranial (anterior) and caudal (posterior) cruciate ligaments. The cranial cruciate ligament (CCL) is commonly injured in both canines and humans (referred to as the ACL in humans).

## Effects of CCL rupture

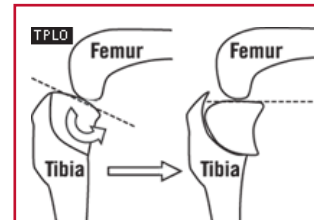
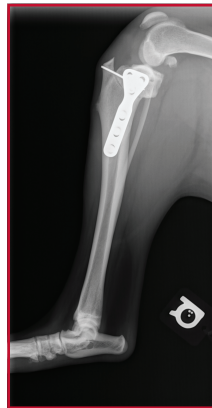Early signs of CCL stress or partial rupture include stiffness or mild lameness. As the CCL continues to tear further, symptoms increase. A full tear usually results in marked lameness in the affected leg. In some cases, the knee will make a clicking or popping sound as the dog walks. This often indicates damage to the cartilage cushions (menisci) within the knee. When the CCL is ruptured, stifle instability ensues. This instability is often described as cranial tibial thrust or "drawer" movement. This shearing motion causes excessive wear of the cartilage on the ends of the bones within the joint, and stretches the surrounding tissues, causing pain. It can also injure the medial meniscus within the stifle. The Tibial Plateau Leveling Osteotomy (TPLO) can eliminate excessive tibial thrust, thus creating a more functionally stable joint and sound gait.

## CCL diagnosis

Diagnosis of a CCL tear is made by palpation

(feeling the knee) and radiographs (x-rays). The radiographic findings associated with a ruptured CCL include osteoarthritic changes and joint effusion (swelling). The actual ligament cannot be seen on the radiographs.

## Description of procedure



A curved cut (osteotomy) through the tibia bone is made using a specially designed saw blade. The top portion of the tibia is then rotated a precise number of degrees in order to level the slope of the tibial plateau and prevent the instability and sliding that occurs with a CCL tear. A bone plate and screws are then placed on the tibia to stabilize it and allow healing to occur.

## Prognosis with TPLO

The TPLO technique has gained acceptance throughout the country due to consistent reports indicating that dogs treated with TPLO have an excellent functional outcome and decreased development of osteoarthritis. The exciting aspect of this technique is the possibility of returning your dog to nearly normal long-term function following CCL rupture (which has not been the typical expectation with any of the traditional techniques attempted before) and the prospect of a reduction in the future progression of arthritis.

## Recovery

Strict confinement will be crucial for several weeks after surgery to avoid potential difficult complications. This will be discussed further during your appointment with the surgeon.